Summer 2020

# The NCVDLS REPORT

Accredited by the American Association of Veterinary Laboratory Diagnosticians

*Veterinary News and Information From North Carolina's Diagnostic Laboratories*

## A Note from Our Director...

North Carolina Department of Agriculture and Consumer Services

Steve Troxler, Commissioner

As you are probably aware, Governor Cooper has initiated a three-phase plan beginning May 8, 2020 to relax restrictions that were put in place to mitigate the spread of the COVID-19 virus. As we move through these three phases toward our new normal, our laboratories will begin to transition into full occupancy, testing, and capabilities. Although we remain fully staffed, we continue to promote social distancing through flexible shift schedules and telework, when possible.

Our laboratory staff continues to perform admirably and maintain our support to you, our valuable clients, during this human health pandemic. During March, April, and May our case load has been consistent with last year's testing numbers and despite our COVID driven challenges we've been able to maintain this level of testing with slight impacts on test availability and turn-around-times. However, please be aware that challenges remain with testing, staffing, and supply shortages and testing availability and turnaround times may still be impacted in coming weeks/months.

Although we have not instituted COVID-19 testing for domestic animals yet, we are researching testing reagents, kits, and supplies and hope to offer this test in the future. To support North Carolina's COVID-19 human testing efforts we have loaned molecular diagnostic equipment to NC State Laboratory of Public Health to bolster their testing capacity while maintaining our in-house surge testing capacity for outbreak disease testing, if needed.

Thank you again for your understanding, patience and support.

Jim Trybus, DVM, DAVCP

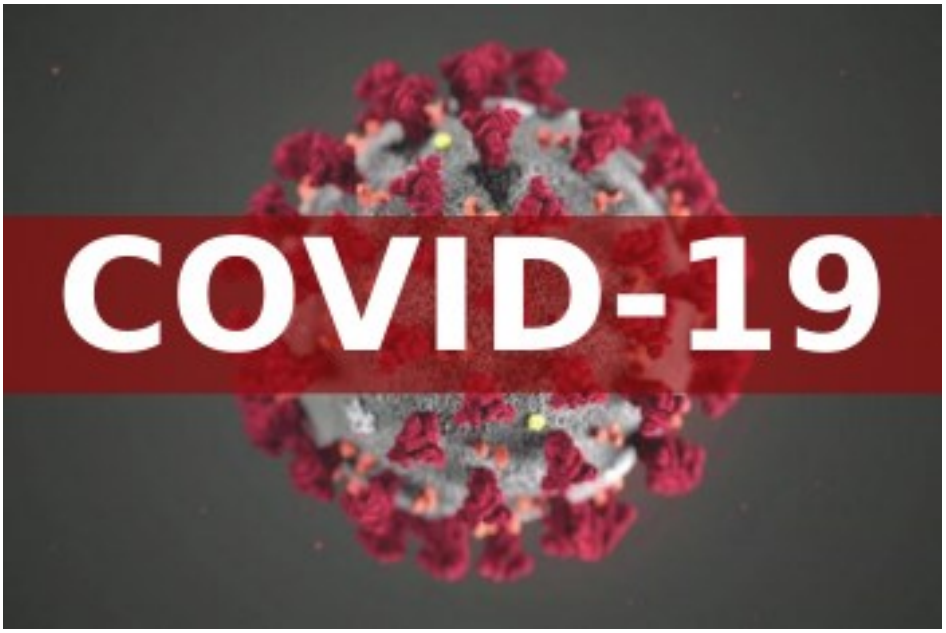

# Introducing NEW Sensititre Micro-broth Dilution Antibiotic Susceptibility Testing at Rollins Laboratory….

We are glad to announce that Rollins laboratory has recently acquired the Sensititre Micro-broth dilution Antibiotic susceptibility testing (AST) method with the help of FDA. We are currently in the process of implementing this method and hope to have it available for our clients in the near future.

Sensititre automated Micro-broth dilution AST method is a great alternative to the current manual Kirby Bauer Disk diffusion AST method, eliminating inaccuracies with easy-to-read endpoints. Micro -broth dilution AST panels also provide us with a wide array of more than 50 antibiotics including Imipenem and Ceftazidime for treating many multi-drug resistant bacteria that we occasionally encounter.

The capacity to perform AST using Micro-broth dilution technique will enable us to determine true MIC (Minimum Inhibitory Concentration) of various antibiotics for bacterial isolates. An automated AST system such as Sensititre provide true MIC results in a reliable, reproducible and accurate manner with greater sensitivity. It is critical for veterinary diagnostic labs to provide clients with the right antibiotic choice to treat and to fight antimicrobial resistance (AMR) and meet antibiotic stewardship goals.

Although Micro-broth dilution AST is more expensive than Disk diffusion AST there will be more antibiotics we could test at the same time. Rollins Laboratory clients will have both options to choose from either Micro-broth dilution AST or inexpensive Disk diffusion AST upon submitting a sample. Micro-broth dilution AST will initially be available only for companion animals and farm animals except poultry.

Having the capability to determine MIC also will help Rollins lab to actively participate in the ongoing FDA VET-LIRN antimicrobial resistance program. This will also facilitate Rollins lab to perform effective AMR surveillance for food-borne and other significant veterinary pathogens. So, stay tuned for the Sensititre Micro-broth AST testing at Rollins and the pricing update at our website:

https://www.ncagr.gov/vet/ncvdl/

# Guidelines for Molecular Diagnostic Testing

# Sample Submissions..

When submitting samples for polymerase chain reaction (PCR) assay, please follow the guidelines given below:

1. Ship the samples on ice, preferably, overnight.
2. While submitting tissue samples, ship only fresh or frozen samples. Fresh tissue is preferred. Formalin fixed samples are not acceptable for PCR testing.
3. While submitting swabs, keep them moist. Dry swabs are not recommended for testing. For regulatory testing, always use the recommended media while collecting specimens (Brain Heart Infusion broth (BHI) is preferred. You may also use Tris-Buffered Tryptose Broth (TBTB) or Nutrient Broth (NB) or Peptone Broth (PB) or commercially available media such as BD Universal Viral Transport 3ml collection kit).
4. Bacterial gel swabs are not suitable for PCR testing. The gel material could inhibit the PCR reaction. Use Dacron or polyester swab with a plastic handle. If you want to use a bacterial culture swab, do not put them in gel or bacterial media after sample collection, but instead put the swab in a sterile tube or in a clean red top vacutainer tube.
5. For testing blood, collect blood in an EDTA (purple colored top) vacutainer tube. Heparinized blood (green top vacutainer tube) is not recommended for PCR testing unless otherwise indicated.
6. When submitting feces, pack the samples in leak-proof containers.

If you have any questions or need additional information on processing, packing and/or shipping samples for PCR testing, please contact the Rollins Laboratory at 919-733-3986.

# Canine Necrotizing Sialometaplasia

**By: Allison Boone, DVM, DAVCP**

Submitted to the histopathology service was the submandibular salivary gland from an 11-year-old, male, castrated, mixed breed dog. Clinical signs included vomiting, weight loss, hypersalivation, and bilaterally enlarged and firm submandibular salivary glands. Histopathology revealed marked, multifocal, coagulative necrosis with thrombosis, ductular hyperplasia and squamous metaplasia (Figures 1-3).

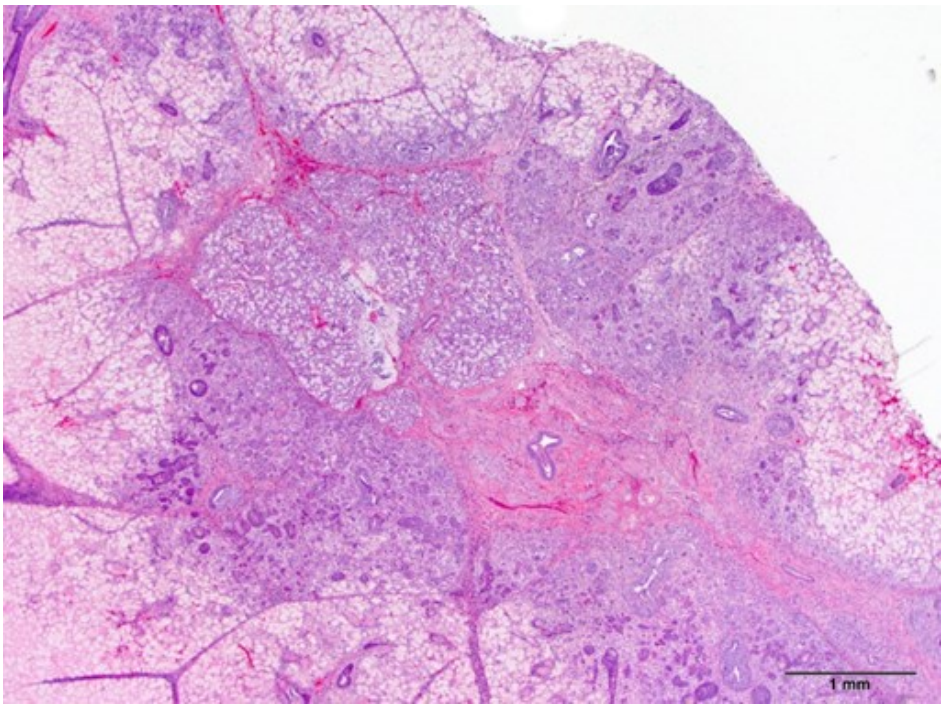


Figure 1

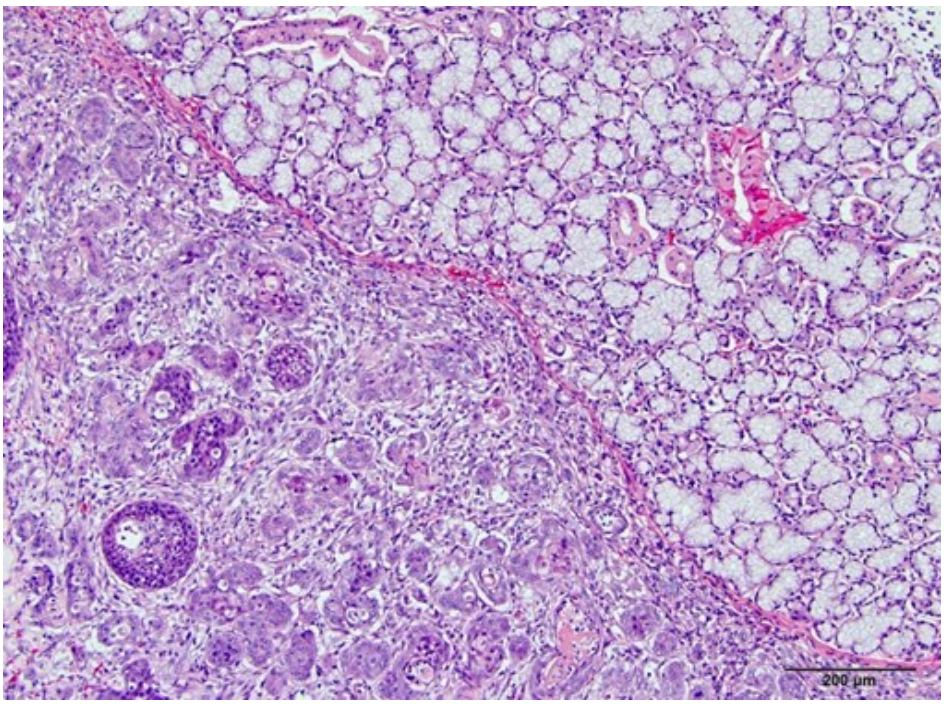


Figure 2

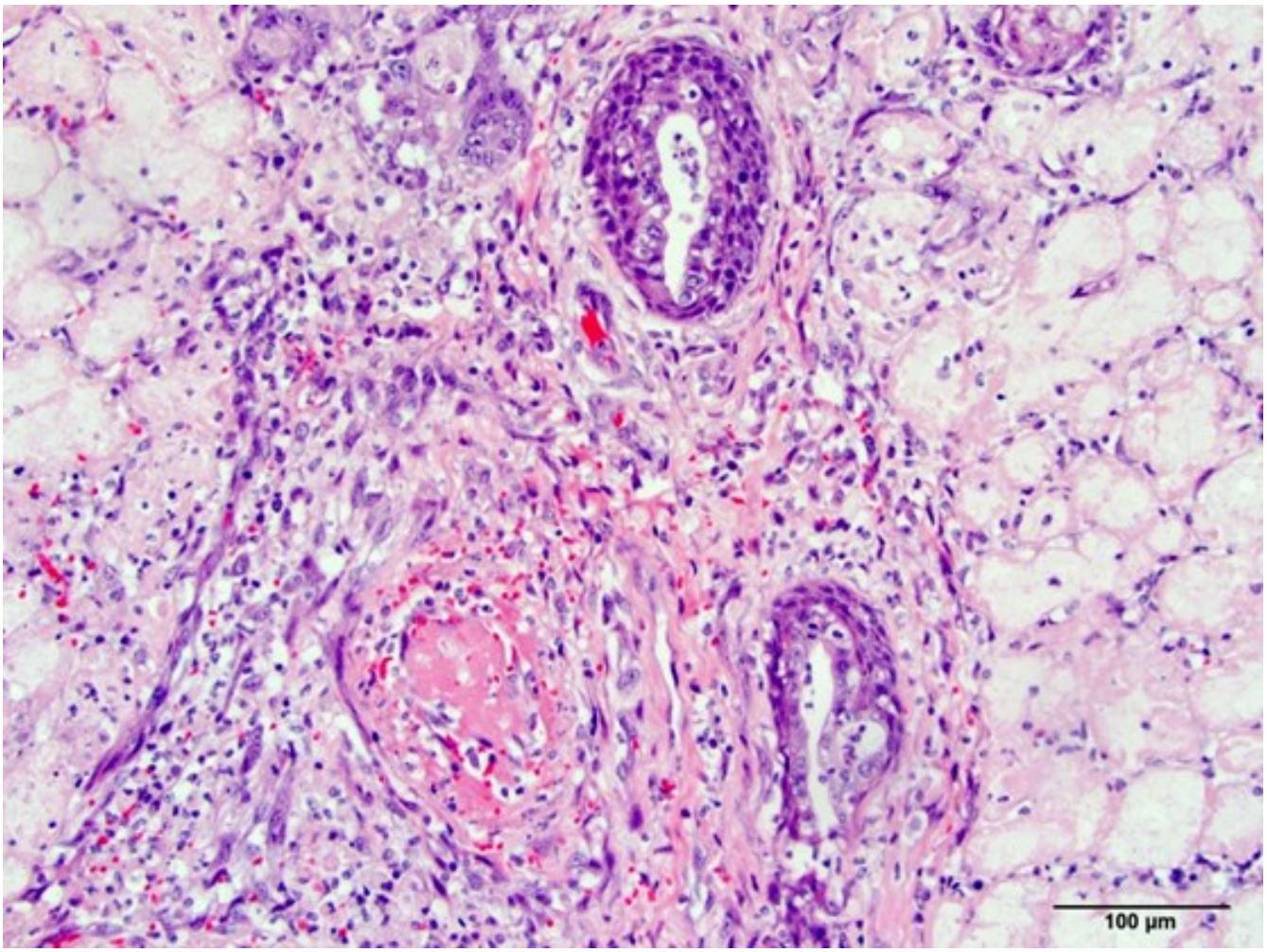


Figure 3

The histopathological lesions are most consistent with the disease known as Canine Necrotizing Sialometaplasia. This is a rare disease, but when seen in dogs, is seen in small breed dogs mostly terriers. The disease is often mistaken for malignant neoplasia. There can be unilateral or bilateral enlargement of the submandibular salivary glands. The clinical signs include gagging, ptyalism, lip-smacking, vomiting, anorexia, and pain. Although the etiology is unknown, proposed etiologies include esophageal lesions, type III hypersensitivity, and vascular compromise secondary to trauma. The disease has been reported to be treated successfully with Phenobarbital; however, the underlying mechanism is unknown. (Ref: Jubb, Kennedy, Palmer (2016) Pathology of Domestic Animals, Elsevier, St. Louis, Missouri, Volume 2 pg. 30)

# Disseminated *Cryptococcus neoformans* in a Dog

**By: Heather Wyss, BVSc**

A five year old, male, neutered, 30 kg Labrador retriever presented for a necropsy and rabies testing after displaying neurological signs. The dog initially presented for acute paraparesis and ataxia. He was treated with prednisone and gabapentin for suspected intervertebral disc disease. A CBC, Superchem, and T4 were within normal limits. An IDEXX 4dx was negative. His condition progressed to tetraparesis and stupor over the following two weeks. He was humanely euthanized. The dog was up to date on vaccinations and was from an urban area.

The only gross necropsy finding consisted of a diffusely thickened and hyperemic pancreas with multifocal to coalescing nodules ranging in size from 2 to 4 mm in diameter scattered across the entire pancreas (figure 1). The thickest area measured 1.5 cm.

Figure 1

Histopathological lesions consisted of multifocal granulomatous meningoencephalomyelitis with intralesional yeast in the brain and spinal cord and multifocal submucosal and muscularis granulomas with intralesional yeast in the intestine (figures 2 and 3). Chronic pancreatitis with fibrosis and multifocal granulomas with intralesional yeast was also identified on histopathology. The yeast present was consistent with *Cryptococcus sp* infection. *Cryptococcus neoformans* was cultured from fresh brain tissue.

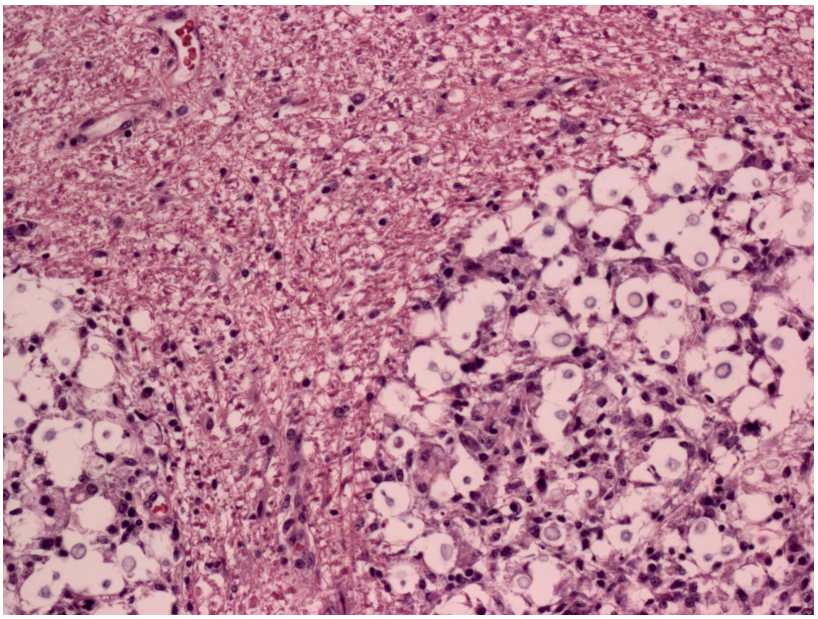

Figure 2

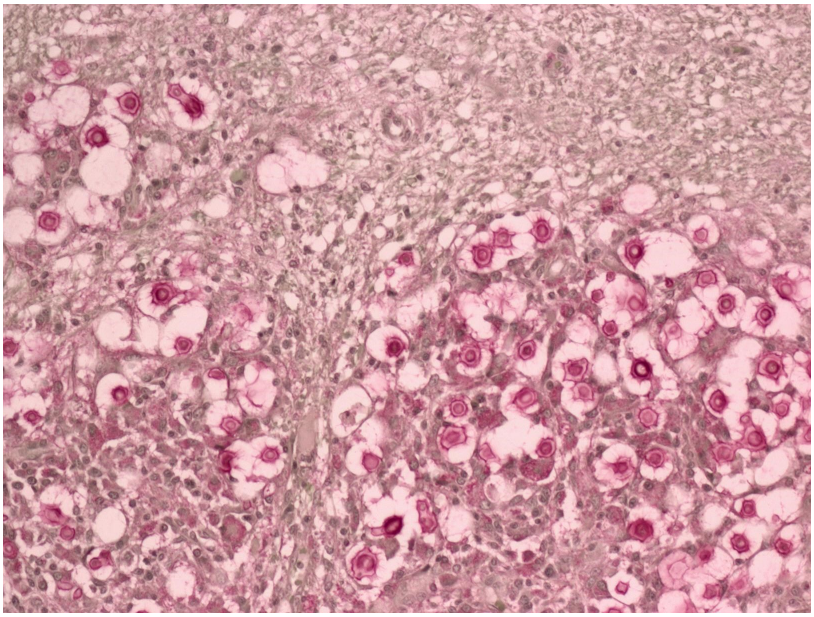

Figure 3

*Cryptococcus neoformans* is a saprophytic, yeast-like fungus with a worldwide distribution. The main reservoir is pigeon droppings but the organism can be found in decayed wood of various trees, in freshwater, in seawater, in tree bark, and in the air. Disruption of surface soils can increase the risk of exposure. The nasal cavity is the likely portal of entry as animals typically become infected through the inhalation of organisms in the environment. The organism may spread hematogenously from the lungs to the CNS, lymphogenous dissemination, or from direct spread from an adjacent infection.

As with any fungal encephalopathy, the prognosis is guarded to poor. Treatment includes the use of oral antifungals. Amphotericin B is recommended for CNS or severe disseminated disease. Flucytosine is can be used in conjunction with Amphotericin B and penetrates the blood-brain barrier well. Patients may deteriorate soon after starting treatment due to the death of the fungal organisms causing inflammation and raising intracranial pressure.

The histopathology photos are courtesy of Dr. Alison Tucker.

# Meningioma in a Caracal

**By: Mahogany Caesar, DVM**

A 19-year-old female Caracal felid had a history of seizures that were medically responsive to Zonisamide for the past year. Days before euthanasia, she became anorexic and intractable to treatment. Necropsy examination identified a 7 x 7 x 6 mm white firm spherical mass in the right thalamus. The brain tumor was histologically consistent with a meningioma. These are rather common central nervous system tumors in domestic and wild animals that typically develop in middle aged to older animals.

Focal expansion of the right thalamus by a 7 x 7 x 6-mm meningioma.

# Pleuroperitoneal Hernia in a Cat

**By: Mahogany Caesar, DVM**

An ovariohysterectomy was performed on a 2-year-old domestic medium hair felid. The cat was found dead in the kennel that same day. On gross examination, a diaphragmatic defect was identified in which approximately 95% of the liver protruded into the thoracic cavity. The defect was incomplete in that it was covered by a thin transparent membrane and there was no direct communication between the abdominal and thoracic cavity. There was severe atelectasis of each lung lobe. No other congenital defects were identified. Findings are consistent with a pleuroperitoneal hernia, which is defined as a subtotal diaphragmatic defect in which the serosa on the thoracic surface of the diaphragm remains intact, thus preventing direct communication between the pleural and peritoneal cavities. They are thought to occur as a congenital defect in which the ingrowth of collagenous or muscular tissue between pleura and peritoneum ceases prematurely. (Source: Journal of Feline Medicine and Surgery. 2009; v11, 873-877)

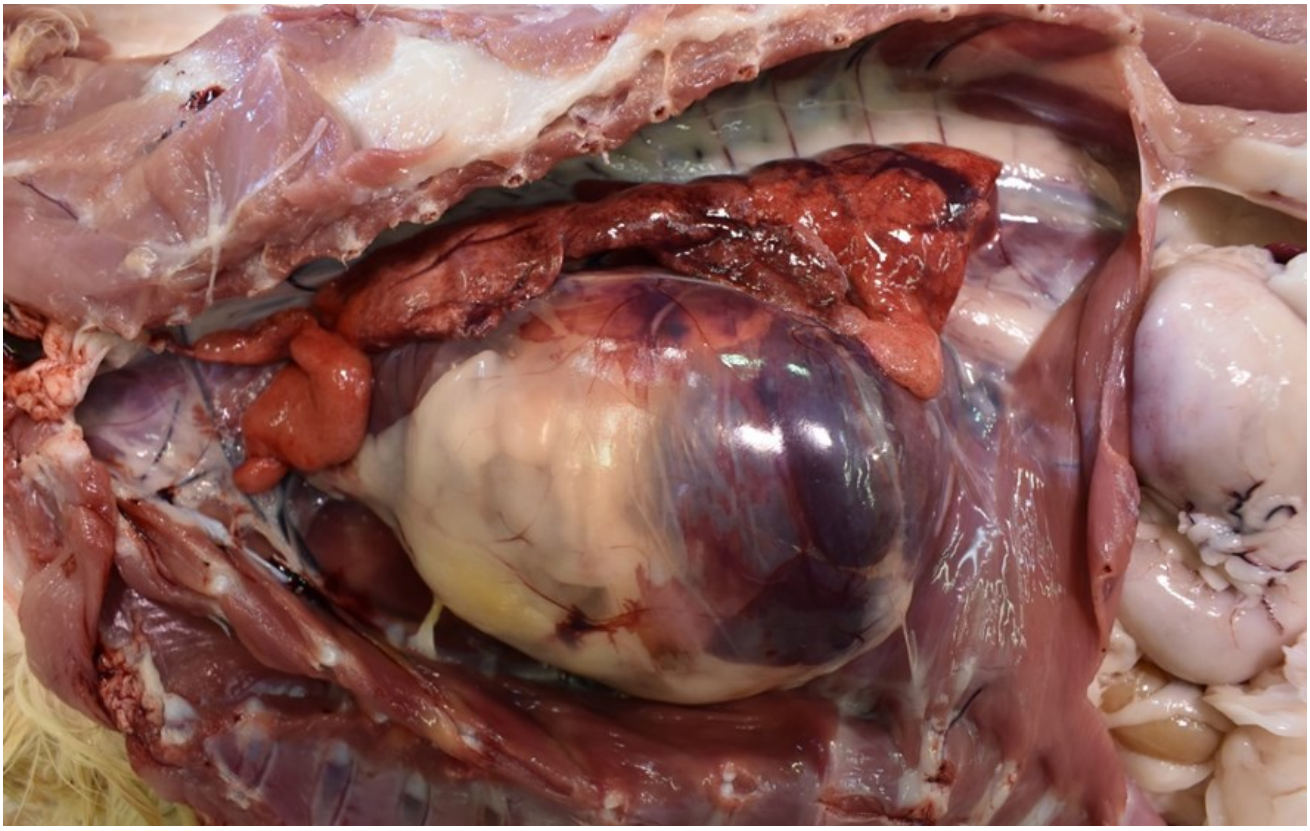

Pleuroperitoneal hernia in an adult domestic felid with a history of resolving respiratory tract infection.

The NCVDLS REPORT

Accredited by the American Association of Veterinary Laboratory Diagnosticians

*Veterinary News and Information From North Carolina's Diagnostic Laboratories*

# Veterinary Staff

## Rollins Laboratory (919) 733-3986

**Director**

| | |
|---|---|
| **Dr. Jim Trybus** | **james.trybus@ncagr.gov** |

**Assistant Director**

| | |
|---|---|
| **Dr. Binu Velayudhan** | **binu.velayudhan@ncagr.gov** |

**Veterinary Diagnosticians**

| | |
|---|---|
| **Dr. Jennifer Haugland** | **jennifer.haugland@ncagr.gov** |
| **Dr. Stacy Robinson** | **stacy.robinson@ncagr.gov** |
| **Dr. Mahogany Wade-Caesar** | **mahogany.wade@ncagr.gov** |

**Veterinary Bacteriologist**

| | |
|---|---|
| **Dr. Anil Thachil** | **anil.thachil@ncagr.gov** |

**Veterinary Pathologists**

| | |
|---|---|
| **Dr. Tahseen Abdul-Aziz** | **tahseen.aziz@ncagr.gov** |
| **Dr. Steven Rushton** | **steve.rushton@ncagr.gov** |
| **Dr. Alison Tucker** | **alison.tucker@ncagr.gov** |
| **Dr. Allison Boone** | **allison.boone@ncagr.gov** |

## Arden Laboratory (828) 684-8188

**Director**

| | |
|---|---|
| **Dr. David Drum** | **david.drum@ncagr.gov** |

## Monroe Laboratory (704) 289-6448

**Director**

| | |
|---|---|
| **Dr. Heather Wyss** | **heather.wyss@ncagr.gov** |

**Veterinary Diagnostician**

| | |
|---|---|
| **Dr. Elise Lavie** | **elise.lavie@ncagr.gov** |

## Elkin Laboratory (336) 526-2499

**Director**

| | |
|---|---|
| **Dr. David Ackerman** | **david.ackerman@ncagr.gov** |

**Veterinary Diagnostician**

| | |
|---|---|
| **Dr. Jessica Kees** | **jessica.kees@ncagr.gov** |